



Effects of Serial Sessions of Activa Mask for the Treatment of Meibomian Gland Dysfunction

Luca Vigo · Marco Pellegrini · Sergio D'Angelo · Francesco Carones ·
Vincenzo Scordia · Giuseppe Giannaccare

Received: September 13, 2022 / Accepted: October 18, 2022
© The Author(s) 2022

ABSTRACT

Introduction: To analyze outcomes on objective ocular surface parameters and subjective symptoms of serial weekly sessions using the Activa mask in patients with meibomian gland dysfunction (MGD).

Methods: This is a prospective study including patients with symptomatic MGD who were treated with four weekly sessions using the

Activa mask (SBM Sistemi, Turin, Italy). Non-invasive ocular surface examination was carried out before (T0) and 2 weeks after the last mask session (T1) using Idra (SBM Sistemi, Turin, Italy) for the measurement of: (1) noninvasive break-up time (NIBUT); (2) lipid layer thickness (LLT); (3) tear meniscus height (TMH); (4) meibomian gland loss (MGL) of upper and lower eyelids. The I-Pen tear osmolarity system (I-Med Pharma Inc, Dollard-des Ormeaux, Quebec, Canada) was used to measure tear osmolarity values. Ocular discomfort symptoms were ascertained by means of the ocular surface disease index (OSDI) questionnaire.

Results: All 25 patients (11 males, 14 females; mean age 57.1 ± 11.9 years) regularly completed the cycle of four mask sessions. No patients used prohibited medications, and no device-related adverse events were noted. At T1, mean values of NIBUT and LLT increased significantly compared to T0 (respectively from 6.0 ± 1.4 to 6.6 ± 1.2 s, $P = 0.043$, and from 53.2 ± 17.4 to 65.3 ± 16.3 nm, $P < 0.001$), while mean values of MGL and tear osmolarity decreased significantly (respectively from 17.1 ± 9.3 to $15.1 \pm 8.0\%$, $P = 0.014$, and from 307.3 ± 12.2 to 301.5 ± 6.8 mOsm/l, $P = 0.005$). In parallel, OSDI score reduced significantly from 62.4 ± 11.7 at T0 to 34.5 ± 11.2 at T1 ($P < 0.001$).

Conclusion: Weekly serial sessions using the Activa mask significantly improved objective parameters of the ocular surface as well as

Luca Vigo and Giuseppe Giannaccare share co-first authorship.

L. Vigo · F. Carones
Carones Ophthalmology Center, Milan, Italy

M. Pellegrini
Department of Ophthalmology, Ospedali Privati
Forlì "Villa Igea", Forlì, Italy

M. Pellegrini
Istituto Internazionale per la Ricerca e Formazione
in Oftalmologia (IRFO), Forlì, Italy

M. Pellegrini
Department of Translational Medicine, University
of Ferrara, Ferrara, Italy

S. D'Angelo
Department of Neuroscience and Rehabilitation,
University of Ferrara, Ferrara, Italy

V. Scordia · G. Giannaccare (✉)
Department of Ophthalmology, University Magna
Græcia of Catanzaro, Viale Europa, 88100
Germaneto, Catanzaro, Italy
e-mail: giuseppe.giannaccare@unicz.it

subjective ocular discomfort symptoms in patients with recalcitrant MGD. As a further benefit from the treatment, patients were able to avoid the use of concomitant medications, apart from tear substitutes, throughout the study.

Keywords: Eye mask; Activa mask; Meibomian gland dysfunction; MGD; Dry eye

Key Summary Points

Why carry out this study?

Activa mask is a novel device designed for in-office management of meibomian gland dysfunction.

Although positive short-term effects (30 min after a single mask session) of Activa mask have been already reported by our group in terms of improvement of both tear film parameters and ocular discomfort symptoms, no information is available on long-term results of multiple mask sessions.

What was learned from the study?

In patients with meibomian gland dysfunction, weekly serial sessions using the Activa mask significantly improved objective parameters of the ocular surface as well as subjective ocular discomfort symptoms.

Use of Activa mask allowed patients not to take concomitant medications apart from tear substitutes (e.g., corticosteroids) for the entire duration of the study.

dysfunction (MGD), a chronic progressive condition characterized by terminal duct obstruction and/or changes in the quality/quantity of gland secretion, represents the main cause of evaporative DED and is therefore a growing area of interest and research [2, 3]. The goal of MGD treatment is to improve the flow of meibomian gland secretions by liquefying materials that otherwise cause obstruction and by stimulating the function of meibomian glands [4–6]. Apart from tear substitutes aiming at restoring the deficient lipid layer of the tear film, eyelid hygiene is the main conservative treatment and involves the use of warm compresses for the local application of heat followed by self-administered mechanical massage of the lid margin to help the release of meibum lipids into the tear film [3]. However, the efficacy of this therapy is often hampered for several reasons. First, patients often perceive eyelid hygiene as tedious and time-consuming, and this may result in poor compliance with treatment [7]. Second, it can be difficult for the patient to perform standardized maneuvers for a reproducible eyelid hygiene. In this regard, the main obstacle is the need for reheating the compresses every 2 min to maintain the therapeutic levels of heat. Furthermore, the mechanical force exerted on the eyelids varies considerably depending on both method employed and patient characteristics.

To overcome these drawbacks, novel devices specifically designed for in-office MGD management—able to produce heating with or without humidity and massaging—have been developed and commercialized in recent years [8–11]. Among these, Activa mask (SBM Sistemi, Turin, Italy) was recently developed, and preliminary data have shown positive short-term effects (30 min after a single mask session) with significant improvement of both tear film parameters and ocular discomfort symptoms when used both alone and in combination with intense pulsed light [12, 13].

The aim of this work is to analyze outcomes on objective ocular surface parameters and subjective symptoms using the Activa mask in weekly serial sessions in patients with symptomatic MGD.

INTRODUCTION

Dry eye is a chronic multifactorial disease of the ocular surface which affects millions of people worldwide, representing the most common conditions encountered in the routine ophthalmic practice [1]. Meibomian gland

METHODS

Study and Patients

This prospective study included MGD patients who attended the ocular surface office of the University Hospital of Catanzaro (Italy) for a routine visit between February 2021 and October 2021. Consecutive patients aged 18–80 years were screened for eligibility according to the following inclusion criteria: presence of MGD defined by the presence of signs consistent with meibomian gland terminal duct obstruction with abnormal quantity and/or quality of meibomian gland secretions; presence of at least one MGD-related ocular symptom such as dryness, foreign body sensation, irritation and burning not satisfactorily controlled with tear substitutes and eyelid hygiene; pathological value of Ocular Surface Disease Index (OSDI) score (≥ 13); noninvasive break-up time (NIBUT) < 10 s (s). Patients were excluded from the study if one of the following conditions was present: active eye inflammation; eyelid malposition; recent (within 3 months) ocular surgery; history of contact lens wearing; risk of retinal detachment such as high myopia, lattice degeneration and retinal break; recent (within 1 month) usage of anti-inflammatory eye drops (topical corticosteroid or cyclosporine).

The study was approved by the local Institutional Review Board and followed the tenets of the Declaration of Helsinki for research involving human subjects. Written informed consent was obtained from all participants after the nature and possible consequences of the study had been explained to them.

Study Treatment

Patients were treated with a recently developed eye mask (Activa, SBM Sistemi, Turin, Italy) (Fig. 1) for four sessions weekly. Technical details concerning the device and the procedure have been described previously [12]. Briefly, through a fully automated touch screen-controlled procedure, the device is able to melt the meibum inside the glands and simultaneously squeeze them. The entire treatment lasts 15 min

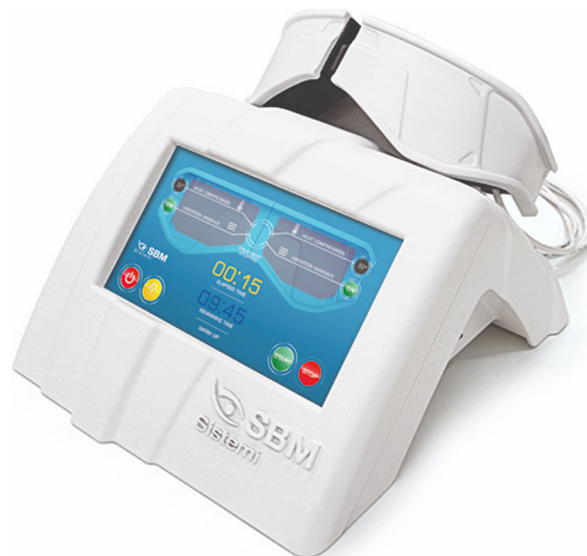

Fig. 1 The Activa mask (SBM Sistemi, Turin, Italy)

and incorporates two phases in the following chronological order: (1) heating (5 min at 42 °C); (2) heating and vibration (10 min of heating at 42 °C and vibration up to 20 Hz).

Ocular Surface Workup

All patients were examined before the first mask session (T0) and 2 weeks after the last session (T1) using Idra (SBM Sistemi, Turin, Italy) for the automated measurement of the following parameters: NIBUT; lipid layer thickness (LLT); tear meniscus height (TMH); meibomian gland loss (MGL) of eyelids [14–16]. The measurements were repeated three times, and the mean value was recorded. Briefly, NIBUT was measured without the need for fluorescein dye after asking the patient to blink three consecutive times and then hold the eyes open. LLT was estimated by observing the interference pattern and colors of the moving lipid tear film. TMH was measured along the lower lid margin immediately below the pupil. Infrared meibography was performed in the upper and lower eyelids, and MGL was calculated using ImageJ image editing software (National Institutes of Health; <http://imagej.nih.gov/ij>) as the percentage of gland loss in relation to the total tarsal area. The I-Pen tear osmolarity system (I-

Med Pharma Inc, Dollard-des Ormeaux, Quebec, Canada) was used to measure tear osmolarity values. Ocular discomfort symptoms were scored using the OSDI questionnaire.

Study Characteristics

During the entire duration of the study, all patients were instructed to instill the same unpreserved hyaluronic acid 0.2%-based eye drops four times daily. Concomitant use of other therapeutic agents (e.g., corticosteroids) for any ophthalmic disease was prohibited throughout the study period.

The primary outcome measures were improvement of NIBUT values and OSDI scores after the cycle of four mask sessions. Secondary outcome measures included increase of LLT and decrease of MGL values at T1.

Sample Size

To determine the required sample size for the study, an a priori power analysis was performed based on the data of the study of Piyacomn et al. [17]. With this assumption, a sample of 17 patients was required to detect a mean change of 14.5 points in OSDI, with a power of 0.80 and P value of 0.05. However, to ensure adequate reliability, we aimed for a sample size of 25 patients.

Statistical Analysis

Statistical analysis was conducted using R (version 4.0.0) and RStudio (version 1.2.5042) software. The Kolmogorov-Smirnov test was used to assess the normality of data. Due to the non-normal distribution, ocular surface parameters before and after the cycle of mask sessions were compared using the Wilcoxon test. $P < 0.05$ was considered statistically significant.

RESULTS

Eighty patients with MGD were assessed for eligibility during the study period. Twenty-five of them (11 males, 14 females; mean age

57.1 ± 11.9 years) fulfilled the criteria and were included in the study. No patient was dropped from the study or used prohibited eye drops, so data from all enrolled patients were ultimately included in the analysis. Demographic and clinical characteristics of these patients are reported in Table 1. Previous medical treatments used by patients for controlling MGD included topical corticosteroids (6 patients, 24% of the total), omega-3 fatty acids (4 patients, 16%), tetracycline ointment (5 patients, 20%) and systemic doxycycline (2 patients, 8%). None of the patients had previously undergone treatment with other in-office devices such as intense pulsed light therapy.

After treatment, mean values of NIBUT and LLT increased significantly (respectively from 6.0 ± 1.4 at T0 to 6.6 ± 1.2 s at T1, $P = 0.043$, and from 53.2 ± 17.4 at T0 to 65.3 ± 16.3 nm at T1, $P < 0.001$), while mean values of MGL and tear osmolarity decreased significantly (respectively from 17.1 ± 9.3 at T0 to 15.1 ± 8.0 at T1, $P = 0.014$, and from 307.3 ± 12.2 at T0 to 301.5 ± 6.8 mOsm/l at T1, $P = 0.005$) (Fig. 2). In parallel, ocular discomfort symptoms improved after treatment with a significant

Table 1 Baseline characteristics of patients included in the study

Parameter	Value
Age (years)	57.1 ± 11.9
Gender (M/F)	11/14
Ethnicity	
European	23 (92%)
Other	2 (8%)
Ocular rosacea	4 (16%)
Ocular allergy	2 (8%)
Duration of MGD (years)	5.3 ± 2.8
History of MGX	16 (64%)
History of MGP	4 (16%)

M male, *F* female, *MGD* meibomian gland dysfunction, *MGX* meibomian gland expression, *MGP* meibomian gland probing

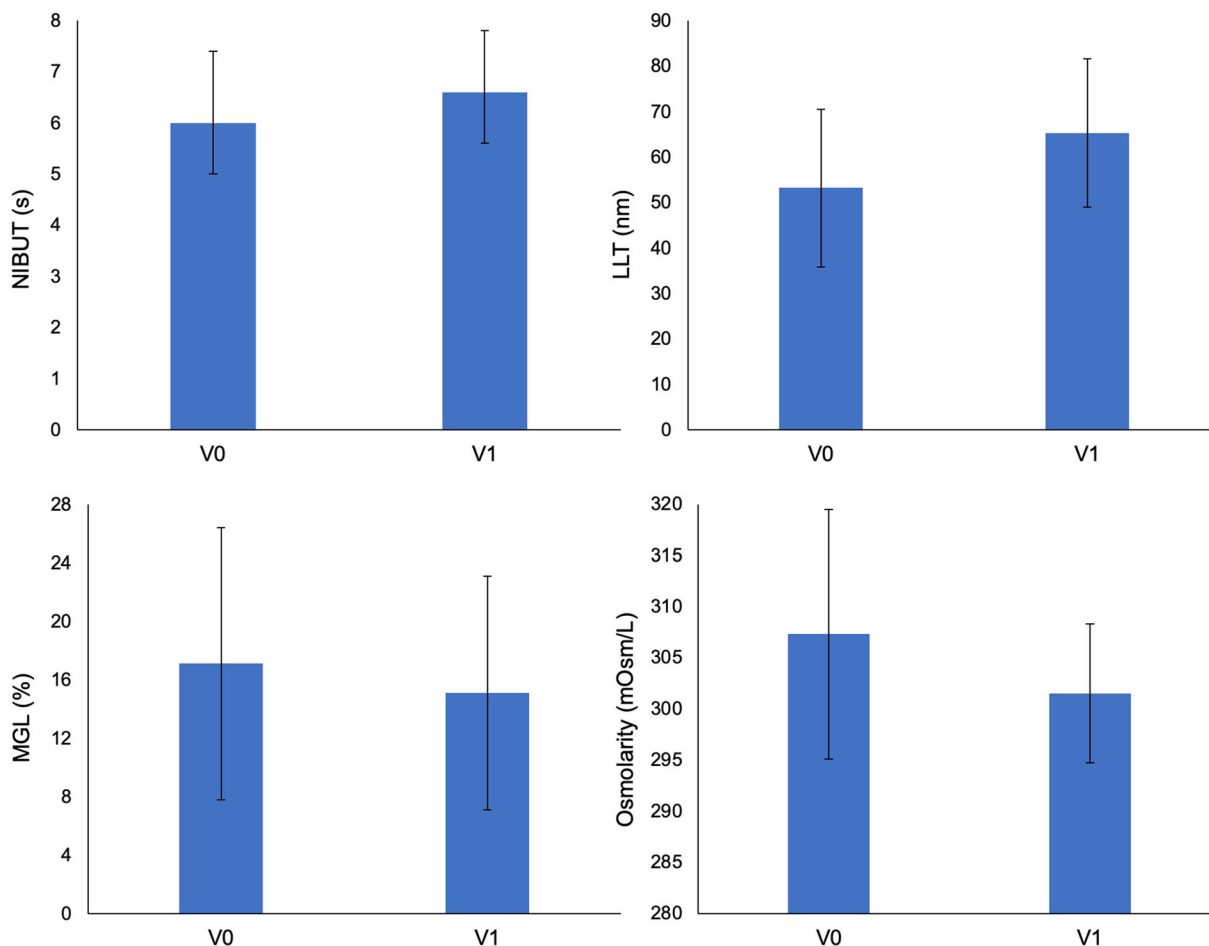


Fig. 2 Charts showing ocular surface parameters before (V0) and after treatment (V1) with the Activa mask

reduction of OSDI score mean value from 62.4 ± 11.7 at T0 to 34.5 ± 11.2 at T1 ($P < 0.001$). Conversely, mean values of TMH did not change significantly after treatment (from 0.25 ± 0.06 to 0.25 ± 0.05 mm, $P = 0.841$).

No device-related adverse events were noted throughout the entire study.

DISCUSSION

Novel therapies are continuously becoming commercially available in the setting of MGD, aiming at helping clinicians and patients to better cope with this disabling disease [18]. The newly developed Activa eye mask has been recently validated in a pilot study that showed

significant improvements of the main parameters of the tear film (NIBUT and LLT) half an hour after a single mask session; in parallel, all patients also reported a distinct improvement in ocular comfort and significant reduction of their symptoms [12]. The mechanism by which this device improves MGD symptoms is thought to be multifactorial: the therapeutic level of heat reached by the device allows liquefying the meibum, which is more fluid at higher temperatures. Heat also acts selectively on tissue and free nerve ending with analgesic effects [14]. On the other hand, the vibration of the mask promotes the release of the liquefied meibum into the tear film [13, 14]. Since the Activa mask has another mechanism of action compared to other devices such as intense pulsed light and low level light therapy, those

devices can potentially be used in combination to increase treatment efficacy.

In the present article, we report the outcomes of a more comprehensive study in terms of treatment and follow-up duration as well as completeness of ocular surface workup. In fact, we analyzed the effects on objective parameters of the ocular surface (NIBUT, LLT, TMH, MGL, tear osmolarity) and on ocular discomfort symptoms of serial weekly sessions of Activa mask in patients with symptomatic MGD. Two weeks after the last mask session, all objective signs improved significantly, except for TMH, whose values were within the normal range already at baseline. In parallel, also ocular discomfort symptoms were significantly ameliorated after these serial sessions. However, it should be pointed out that the subjective score continued to remain in the pathological range even after mask sessions, suggesting the need to repeat further cycles of treatment over time for better controlling symptoms. Additional positive results are related to the high compliance of patients who completed the entire cycle of four sessions, avoiding the use of prohibited eye drops such as corticosteroids or antibiotics in the totality of cases throughout the entire study.

The post-treatment improvements of NIBUT, LLT and ocular symptoms are consistent with those reported with other devices used for similar tasks, namely the LipiFlow and iLux systems, which were recently compared in a randomized clinical trial [19]. In these cases, eyelid heat and vibrating therapy designed to melt the meibum increased lipid re-incorporation into the tear film, thus reducing both the rate of aqueous evaporation and degree of tear osmolarity. The longitudinal improvement of MGL after treatment needs to be further elucidated. Reversibility of the MGL remains controversial, particularly after short-term follow-up studies [20]. On one hand, the improvement of gland dropout after conventional treatments for MGD based on tear substitutes and eyelid hygiene has been described [21]. On the other, another study did not detect any significant changes in meibography after a thermodynamic treatment for MGD [22]. Since it is reasonable to consider revitalizing atrophic glands

impossible, the decrease of MGL after such treatment may be related to the changes in the appearance of meibomian glands that become clearer and more distinguishable from the tarsal plate. In this regard, a new index of meibomian gland health called “vagueness” has been recently described and quantified, showing good reliability and diagnostic efficacy [23]. In the near future, the implementation of this new parameter in the diagnostic workup will add more detailed information about the longitudinal changes of meibomian glands after eyelid therapies.

The present study suffers from several limitations that deserve mentioning. Among these, the main one concerns the study design that did not include a control group of patients treated with tear substitutes only. However, we enrolled MGD patients who did not control their symptoms using conventional treatments (e.g. tear substitutes, eyelid hygiene, meibomian gland expression) as confirmed by the frank pathological values of OSDI score at baseline. Thanks to the mask sessions, patients were able to better cope with their symptoms without needing to add other medications such as antibiotics or corticosteroids. However, ocular discomfort score remained in the pathological range after the cycle of treatment, and a study with a longer follow-up is required to ascertain whether symptoms can further improve with additional mask sessions. Moreover, since all patients were examined at baseline and after 2 weeks of treatment, the study could not explore the impact of the duration of the treatment on its efficacy.

CONCLUSIONS

In conclusion, serial weekly sessions of Activa mask use significantly improved all objective parameters of the ocular surface as well as subjective discomfort symptoms in MGD patients who were using conventional treatment without satisfaction. Furthermore, the benefits from the treatment allowed patients not to use concomitant medications, apart from tear substitutes, for the entire duration of the study.

ACKNOWLEDGEMENTS

We thank the participants of the study.

Funding. No funding or sponsorship was received for this study or publication of this article.

Authorship. All authors meet the International Committee of Medical Journal Editors (ICMJE) criteria for authorship for this article, take responsibility for the integrity of the work as a whole, and have given their approval for this version to be published.

Author Contributions. All authors contributed to the study conception and design. Material preparation, data collection and analysis were performed by Luca Vigo, Marco Pellegrini, Francesco Carones and Sergio D'Angelo. The first draft of the manuscript was written by Luca Vigo and Giuseppe Giannaccare. All authors commented on previous versions of the manuscript. All authors read and approved the final manuscript.

Disclosures. Luca Vigo, Marco Pellegrini, Sergio D'Angelo, Francesco Carones, Vincenzo Scordia and Giuseppe Giannaccare confirm that they have no conflicts of interest to disclose.

Compliance with Ethics Guidelines. Informed consent was acquired from all the participants, and the study was carried out in accordance with the Declaration of Helsinki of 1964 and its later amendments, with approval from the local institutional ethics committee (Comitato Etico Regione Calabria Sezione Area Centro).

Data Availability. The datasets generated during and analyzed during the current study are available from the corresponding author on reasonable request.

Open Access. This article is licensed under a Creative Commons Attribution-NonCommercial 4.0 International License, which permits any non-commercial use, sharing, adaptation, distribution and reproduction in any medium

or format, as long as you give appropriate credit to the original author(s) and the source, provide a link to the Creative Commons licence, and indicate if changes were made. The images or other third party material in this article are included in the article's Creative Commons licence, unless indicated otherwise in a credit line to the material. If material is not included in the article's Creative Commons licence and your intended use is not permitted by statutory regulation or exceeds the permitted use, you will need to obtain permission directly from the copyright holder. To view a copy of this licence, visit <http://creativecommons.org/licenses/by-nc/4.0/>.

REFERENCES

1. Stapleton F, Alves M, Bunya VY, Jalbert I, Lekhanont K, Malet F, Na K-S, Schaumberg D, Uchino M, Vehof J, Viso E, Vitale S, Jones L. TFOS DEWS II epidemiology report. *Ocul Surf*. 2017;15(3):334–65.
2. Nelson JD, Shimazaki J, Benitez-del-Castillo JM, Craig JP, McCulley JP, Den S, Foulks GN. The international workshop on meibomian gland dysfunction: report of the definition and classification subcommittee. *Invest Ophthalmol Vis Sci*. 2011;52:1930–7.
3. Sabeti S, Kheirkhah A, Yin J, Dana R. Management of meibomian gland dysfunction. *Surv Ophthalmol*. 2020;65:205–17.
4. Giannaccare G, Taroni L, Senni C, Scordia V. Intense pulsed light therapy in the treatment of meibomian gland dysfunction: current perspectives. *Clin Optom (Auckl)*. 2020;11:113–26.
5. Thode AR, Latkany RA. Current and emerging therapeutic strategies for the treatment of meibomian gland dysfunction (MGD). *Drugs*. 2015;75:1177–85.
6. Qiao J, Yan X. Emerging treatment options for meibomian gland dysfunction. *Clin Ophthalmol*. 2013;7:1797–803.
7. Alghamdi YA, Camp A, Feuer W, Karp CL, Wellik S, Galor A. Compliance and subjective patient responses to eyelid hygiene. *Eye Contact Lens*. 2017;43:213–7.
8. Valencia-Nieto L, Novo-Diez A, Blanco-Vasquez M, Lopez-Miguel A. Therapeutic instruments targeting

- meibomian gland dysfunction. *Ophthalmol Ther*. 2020;9:797–807.
9. Vigo L, Taroni L, Bernabei F, Pellegrini M, Sebastiani S, Mercanti A, Di Stefano N, Scorcia V, Carones F, Giannaccare G. Ocular surface workup in patients with meibomian gland dysfunction treated with intense regulated pulsed light. *Diagnostics (Basel)*. 2019;9:147.
 10. Vigo L, Giannaccare G, Sebastiani S, Pellegrini M, Carones F. Intense pulsed light for the treatment of dry eye owing to meibomian gland dysfunction. *J Vis Exp*. 2019. <https://doi.org/10.3791/57811>.
 11. Giannaccare G, Pellegrini M, Carnovale Scalzo G, Borselli M, Ceravolo D, Scorcia V. Low level therapy versus intense pulsed light for the treatment of Meibomian gland dysfunction: preliminary results from a prospective randomized comparative study. *Cornea*. 2021. <https://doi.org/10.1155/2021/1370001>.
 12. Vigo L, Pellegrini M, Carones F, Scorcia V, Giannaccare G. Short-term effects of a novel eye mask producing heat and vibration for the treatment of meibomian gland dysfunction: a pilot study. *J Ophthalmol*. 2021;2021:1370002.
 13. Vigo L, Pellegrini M, Carones F, Scorcia V, Giannaccare G. Outcomes of serial sessions of activa mask combined with intense pulsed light therapy in patients with Meibomian gland dysfunction. *BMC Ophthalmol*. 2022;22(1):313. <https://doi.org/10.1186/s12886-022-02538-0>.
 14. Vigo L, Pellegrini M, Bernabei F, Carones F, Scorcia V, Giannaccare G. Diagnostic performance of a novel noninvasive workup in the setting of dry eye disease. *J Ophthalmol*. 2020. <https://doi.org/10.1155/2020/5804123>.
 15. Giannaccare G, Vigo L, Pellegrini M, Sebastiani S, Carones F. Ocular surface workup with automated noninvasive measurements for the diagnosis of meibomian gland dysfunction. *Cornea*. 2018;37:740–5.
 16. Di Cello L, Pellegrini M, Vagge A, Borselli M, Ferro Desideri L, Scorcia V, Traverso CE, Giannaccare G. Advances in noninvasive diagnosis of dry eye disease. *Appl Sci*. 2021;11(21):10384.
 17. Piyacomn Y, Kasetsuan N, Reinprayoon U, Satitpitakul V, Tesapirat L. Efficacy and safety of intense pulsed light in patients with meibomian gland dysfunction—a randomized, double-masked, sham-controlled clinical trial. *Cornea*. 2020;39(3):325–32.
 18. Messmer EM. Novel current and future therapy options for treatment of dry eye disease. *Ophthalmologie*. 2018;115(2):100–6.
 19. Tauber J, Owen J, Bloomenstein M, Hovanesian J, Bullimore MA. Comparison of the iLux and the LipiFlow for the treatment of meibomian gland dysfunction and symptoms: a randomized clinical trial. *Clin Ophthalmol*. 2020;14:405–18.
 20. Bernabei F, Versura P, Pellegrini M, Moscardelli F, Bonifazi F, Sessa M, et al. Longitudinal analysis of infrared meibography in patients undergoing hematopoietic stem cell transplantation. *Cornea*. 2020;39:812–7.
 21. Yin Y, Gong L. Reversibility of gland dropout and significance of eyelid hygiene treatment in meibomian gland dysfunction. *Cornea*. 2017;36:332–7.
 22. Finis D, Konig C, Hayajneh J, Borrelli M, Schrader S, Geerling G. Six-month effects of a thermodynamic treatment for MGD and implications of meibomian gland atrophy. *Cornea*. 2014;33:1265–70.
 23. Yin Y, Gong L. The quantitative measuring method of meibomian gland vagueness and diagnostic efficacy of meibomian gland index combination. *Acta Ophthalmol*. 2019;97:e403–9.